



**PATIENT**

Bella Goodrow

**SPECIES**

Canine

**BREED**

Miniature Poodle

**SEX**

Female Spayed

**AGE**

13 years

**WEIGHT**

17lbs

**INTERPRETED BY**

Maggie Machen Lamy, DVM DACVIM (Cardiology)

**IMAGING PERFORMED BY**

Pamela Harrigan, RDCS

**HOSPITAL NAME**

Mass Veterinary Services

**REFERRING VET**

Dr. Masloski

**INVOICE**

26197

**DATE**

9/6/22

**PRESENTING CLINICAL SIGNS**

History: Recheck echo. History chronic valvular disease - Stage B2. Currently, Bella is doing well with some improvement in her cough. Eating well with normal activity level. Improved coughing: 2-3 times a day and generally after exertion. On exam: NSR, grade III/VI murmur with PMI left apical area radiating to the right, PSS, lung fields clear. BP: 150 mmHg. Current medications: 1) Metronidazole 250mg 1/4 tab daily 2) Verti mega probiotic daily 3) Pimobendan/vetmedin 2.5mg 1 tab twice a day 4) Vicox tabs 5) Hydrocodone with homatropine/hycodan 5/1.5mg 1/2 tab twice a day \*No sedation for study. -Pertinent previous echo findings (3/15/22 Maggie Machen Lamy, DVM, DACVIM-Cardiology): LA 3.0 cm; LA:Ao 1.76; LV 3.7 cm; moderate LAE; mild LVE; moderate-severe MR; mild-moderate TR (3.1 m/s; 39 mmHg ); early pulmonary hypertension.

**ECHOCARDIOGRAM FINDINGS**

2D, m-mode, color flow and Doppler imaging is available. **Left ventricle:** The LV diameter is mildly increased with hyperdynamic function. LV wall thicknesses are normal. **Left atrium:** The left atrium is moderately dilated. **Mitral valve:** The mitral valve is diffusely thickened with prolapse into the left atrial lumen. Moderate eccentric mitral regurgitation with a normal velocity. **Aortic valve/Aorta:** The aortic valve is mildly thickened. Normal aortic outflow velocity; laminar flow. Mild to moderate aortic insufficiency. **Right ventricle:** Normal right ventricular diameter and morphology indicating no overt evidence of pulmonary arterial hypertension. **Right atrium:** Normal RA dimension. **Tricuspid valve:** The tricuspid valve appears mildly thickened with mild tricuspid regurgitation. Velocity consistent with early pulmonary hypertension. **Pulmonic valve/Pulmonary artery:** The pulmonic valve is normal in morphology and mobility. No pulmonic insufficiency. Normal RVOT velocity; laminar flow. **Pericardium/other:** No pericardial or pleural effusion noted. No obvious cardiac masses. **Heart rhythm:** ECG reveals a sinus rhythm with an average HR of 150bpm.

**2-Dimensional Measurements**

Ao diam (cm)	1.7
LA diam (cm)	2.8
LA:Ao (Swe)	1.6
IVS thickness (cm)	0.8
LVID diastole (cm)	3.4
PW thickness (cm)	0.8
LVID systole (cm)	1.8
FS (%)	47

**Doppler Measurements**

PV Vmax (m/s)	1.2
AoV Vmax (m/s)	2.6
MR Vmax (m/s)	6.4
TR Vmax (m/s)	3.1
TR PG (mmHg)	39

**INTERPRETATION OF THE FINDINGS**

Chronic degenerative valve disease persists with evidence of stability. Moderate mitral and mild tricuspid regurgitation are slightly improved comparatively, likely due to Pimobendan administration. The aortic leak is similar and pulmonary pressures unchanged. No additional issues are identified.



**PATIENT**  
Bella Goodrow

Given these findings, no additional medications are warranted. Continue Pimobendan is recommended as prescribed. Continued assessment of progression in the future will help predict long term outcome, however prognosis is guarded at this stage (B2).

**SPECIES**  
Canine

**RECOMMENDATIONS**

- Continue Pimobendan 0.3mg/kg PO q12h.
- Omega fatty acid supplementation and mild salt restriction may be of some long-term benefit.
- Anesthetic risk is considered mild if needed. Cardiac protective drug choices (opioid/benzodiazepine premedication, propofol or alfaxalone induction, isoflurane gas) are recommended. Pre-oxygenate for 5-10 minutes prior to induction. Monitor for arrhythmias, hypotension, and hypoxia both intra and post-operatively and intervene as necessary. Mild IV fluid restriction is recommended to avoid fluid overload. Avoid heart rate stimulating drugs such as atropine unless clinically indicated.
- Monitor for development of a cough, labored breathing, exercise intolerance or collapse episodes.

**BREED**  
Miniature Poodle

**SEX**  
Female Spayed

**AGE**  
13 years

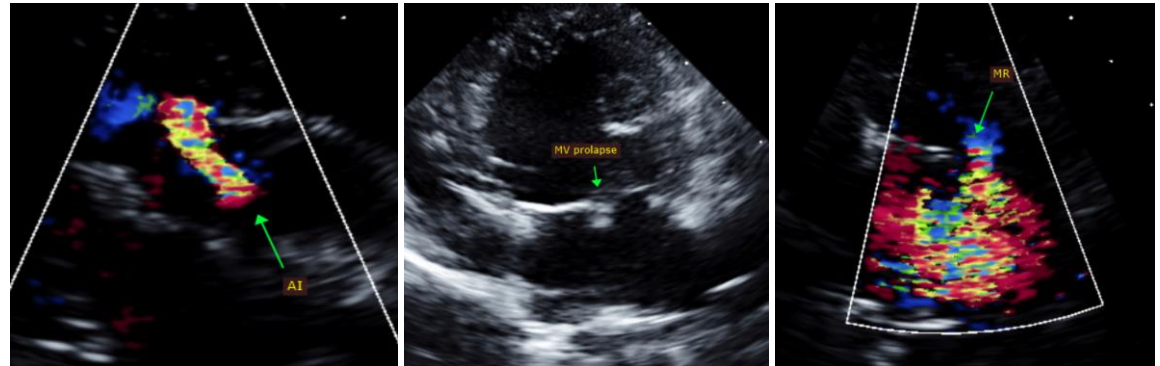
**PLAN**

- Recommend conservative monitoring with a recheck echocardiogram in 6 months, sooner if any development of clinical signs.

**WEIGHT**  
17lbs

**IMAGES**

**INTERPRETED BY**  
Maggie Machen  
Lamy, DVM  
DACVIM (Cardiology)



**IMAGING PERFORMED BY**  
Pamela Harrigan,  
RDCS

**HOSPITAL NAME**  
Mass Veterinary Services

The information and recommendations provided are based on the images presented by the referring veterinarian. No evaluation can be communicated regarding pathology that was not visible in the image/video clips provided.

**REFERRING VET**  
Dr. Masloski

Thank you for this referral. This report was generated using transcription software, and minor dictation errors may be present. If the clinical or image interpretation does not parallel your findings or if I can be of any further assistance, please contact me.

**INVOICE**  
26197

**Maggie Machen Lamy, DVM**  
Diplomate of the American College of Veterinary Internal Medicine (Cardiology)  
info@sonopath.com

**DATE**  
9/6/22

**Echocardiogram performed by:** Pamela Harrigan, RDCS  
Pet Animal Ultrasound Service (4paus.com)